

# ACTICOAT Flex 3 case study

## Chronic non-healing leg ulcer



Authors: Sue Murray and Ann Pardoe, Tissue Viability Team, Walton Forest Community Services.

### Background

22-year-old male patient with an ulcer to the medial malleolus of the left leg. Patient suffered from chronic venous disease and was under hospital care for a wound biopsy and scan. The wound was “scraped” and debrided on alternate weeks. The hospital recommended a hydrofibre and multi-component bandaging. There had been no improvement for the last two years with the ulcer becoming larger in size. The patient had increased pain, erythema, malodour and increased exudate levels and a referral was made to the Tissue Viability team.

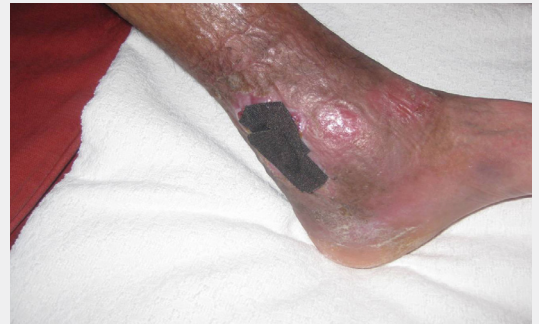
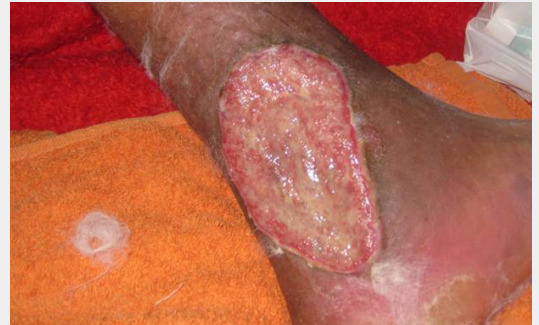### Treatment

ACTICOAT Flex was used as a primary dressing to eliminate the odour-causing bacteria and PROFORE° multi-layer compression bandaging was applied to the wound as this was distressing to the patient. The patient was very anxious that he had a wound infection.

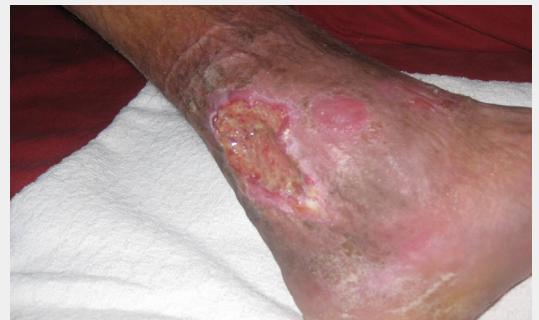### Results

Improvement was seen by the first dressing change and therefore the patient was discharged under the care of the Leg Ulcer clinic.

The wound healed within four months of referral to the Tissue Viability Team.



Improvement to ulceration after 3 weeks of treatment with ACTICOAT Flex



Smith & Nephew  
Croxley Park  
Building 5, Lakeside  
Hatters Lane, Watford  
Hertfordshire WD18 8YE

[www.smith-nephew.com/uk](http://www.smith-nephew.com/uk)

°Trademark of Smith & Nephew  
All Trademarks acknowledged  
©May 2017 Smith & Nephew  
08612

T +44 (0) 1923 477100  
F +44 (0) 1923 477101

Supporting healthcare professionals for over 150 years